

# Laparoscopic Management of Spontaneous Retroperitoneal Hemorrhage

Juan A. Peña<sup>a</sup> Miriam Serrano<sup>a</sup> Marco Cosentino<sup>a</sup> Antonio Rosales<sup>a</sup>  
Ferran Algaba<sup>b</sup> Juan Palou<sup>a</sup> Humberto Villavicencio<sup>a</sup>

Departments of <sup>a</sup>Urology and <sup>b</sup>Pathology, Fundació Puigvert, Barcelona, Spain

## Key Words

Hemorrhage · Angiomyolipoma · Laparoscopy

## Abstract

Wunderlich's syndrome is a spontaneous nontraumatic massive retroperitoneal hemorrhage. It is usually secondary to a renal neoplasm, with angiomyolipoma being the most frequent followed by renal cell carcinoma. The management of spontaneous retroperitoneal bleeding varies depending on the hemodynamic status of the patient. We present the first report of a transperitoneal laparoscopic nephrectomy in a patient with spontaneous retroperitoneal active bleeding secondary to a right renal mass.

Copyright © 2011 S. Karger AG, Basel

## Introduction

Wunderlich's syndrome (WS) is a spontaneous nontraumatic massive retroperitoneal hemorrhage. It is usually secondary to a renal neoplasm, with angiomyolipoma (AML) being the most frequent followed by renal cell carcinoma. Vascular diseases are the next most common etiology (particularly polyarteritis nodosa) [1]. The management of spontaneous retroperitoneal bleeding varies

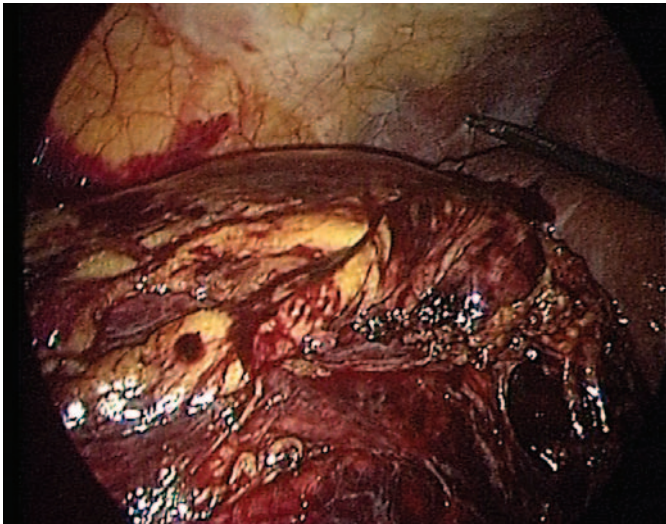
depending on the hemodynamic status of the patient. Conservative management is usually adopted in hemodynamically stable patients, whereas a radiological or surgical approach is the method of choice in unstable patients.

We present the first report of a transperitoneal laparoscopic nephrectomy in a patient with spontaneous retroperitoneal active bleeding secondary to a right renal mass.

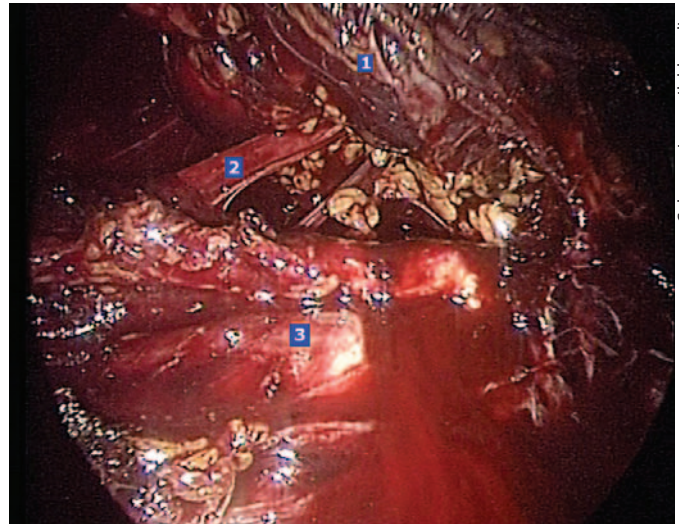
## Case Report

We present the case of a 62-year-old female with a known history of AML of the right kidney referred to our institution by the emergency room for right flank pain, nausea, and vomiting in a setting of progressively decreasing levels of hemoglobin. A CT scan performed in the emergency room revealed a large right retroperitoneal hematoma. The past medical and surgical history included allergy to iodine, dyslipidemia, laparoscopic hysterectomy, and left hemicolectomy.

In the first 24 h following admission the patient remained hemodynamically stable. On day 2, the patient was transfused 4 units of blood due to a marked decrease in hemoglobin levels. Despite this the patient became hemodynamically unstable. Since selective embolization was not deemed possible due to the iodine allergy, the decision to explore the patient was made. The patient was offered an open versus laparoscopic approach and she opted for the minimally invasive option.



Color version available online



Color version available online

**Fig. 1.** Intraoperative endoscopic view of the retroperitoneal hematoma.

**Fig. 2.** Intraoperative endoscopic view of the vena cava and the ureter. 1 = Kidney. 2 = Ureter. 3 = Vena cava.

The procedure was performed through transperitoneal access with 4 trocars (two 11 mm and two 5 mm; Ethicon Endo-Surgery, Inc., Cincinnati, Ohio, USA). The first trocar was introduced under direct vision using the open technique. It was immediately possible to localize the right kidney which was enlarged and completely embedded in a perirenal hematoma (fig. 1). The colon was displaced by the hematoma. It was mobilized and the inferior rim of the liver was retracted ventrally by a grasper. The second portion of the duodenum was dissected and the anterior surface of the vena cava was thus exposed. All of the vascular structures were surrounded by inflammatory lymph nodes that made the dissection more difficult (fig. 2). During the entire procedure there was persistent bleeding from the hematoma's surface. The renal artery was controlled using Hem-o-lok® (Teleflex Medical, USA) and the renal vein using Endo-GIA® (Ethicon Endo-Surgery). Surgical time was 250 min and blood loss was 2,000 cm<sup>3</sup> (including the hematoma blood content). The diameter of the nephrectomy specimen was 14 × 10 cm. The final pathology confirmed an AML. The patient received 3 intraoperative units of blood. The postoperative course was uneventful, and since the patient was hemodynamically stable she was discharged on day 5.

## Discussion

WS is a clinical condition defined as a spontaneous nontraumatic retroperitoneal hemorrhage confined to the subcapsular and perirenal spaces [2]. It is usually secondary to a renal neoplasm (with AML being the most frequent followed by renal cell carcinoma). Vascular diseases are the next most common etiology (particularly polyarteritis nodosa) [1]. The onset of the symptoms can

be insidious or sudden, as in Lenk's classic triad: flank pain, a palpable mass, and hypovolemic shock [2].

Clinical suspicion is crucial for an early diagnosis and must be followed by a meticulous physical examination and laboratory analysis [3]. Ultrasonography is a useful tool for the rapid identification of renal/perirenal abnormalities. Although its findings are not specific, it is a quick and inexpensive examination and therefore very useful to begin with the diagnostic process [2, 3]. Nevertheless, the best imaging test for the diagnosis of perirenal hemorrhage is an abdominal CT scan performed with and without intravenous contrast. This allows the visualization of active bleeding [2, 4]. If no underlying cause or source of bleeding is detected on CT, a renal arteriography may help identify active bleeding, thus allowing selective embolization [4].

The treatment of patients with a spontaneous renal hematoma is determined by the hemodynamic status. In hemodynamically stable patients, clinical observation is accepted as the standard of care [5]. However, since spontaneous bleeding may hide a malignant process, some authors recommend surgical exploration in all cases [6, 7]. If a kidney tumor is found to be the source of the bleeding, nephron-sparing surgery should be attempted when possible to preserve kidney function [8]. However, its use is limited by the extreme difficulty of these cases. Therefore, a nephrectomy is most commonly performed [6, 8]. When the patient is not stable despite blood transfusions, it is imperative to act aggressively with either a radiolog-

ical approach or a surgical approach. The fact that this patient was allergic to iodine rendered embolization unsafe, and therefore surgical treatment was deemed mandatory. The patient was offered an open versus laparoscopic approach and she opted for the minimally invasive approach.

Laparoscopic exploration provides a minimally invasive surgical option. Moreover, the pressure induced by a pneumoperitoneum may help to initially contain the hemorrhage, aspirate the blood coagulum, and control hemostasis without increasing blood loss. Laparoscopy has been reported to be a safe approach for managing significant hemorrhage during (vascular injuries) and after (postoperative bleeding) urological procedures, decreasing patients' morbidity [9, 10]. Laparoscopic nephrectomy has been reported previously as a delayed treatment option after a spontaneous retroperitoneal hematoma. Hernandez et al. [6] described 4 cases of transperitoneal laparoscopic nephrectomy (with a partial nephrectomy in one of them) performed 3 or 6 months after a spontaneous hemorrhage. The difficulty of dissection due to the fibrosis secondary to resorption of the hematoma is highlighted by the authors. Hence, the laparoscopic approach should only be attempted by surgeons comfortable with laparoscopic techniques.

To our knowledge this is the first report on laparoscopic surgery in WS during the acute phase. In this case the laparoscopic nephrectomy was performed through a transperitoneal approach. We were able to reproduce all

the steps that we normally perform during a radical nephrectomy for kidney cancer. However, in this case we found to be particularly challenging the large size of the kidney, the continuous bleeding from the hematoma that hindered the correct vision of the surgical field, and the presence of inflammatory lymph nodes surrounding the vascular structures that made the dissection more difficult.

One of the principal limitations of this approach is that only very experienced laparoscopists can perform the surgery. As such, this technique remains an alternative in selected patients and centers.

## Conclusions

Although a laparoscopic approach in acute WS is feasible, it could be technically challenging for several reasons: the large size of the mass, continuous draining of the hematoma, and presence of perivascular inflammatory tissue. The laparoscopic approach can offer the advantages of minimally invasive surgery with decreased intraoperative bleeding due to the increased pressure secondary to the pneumoperitoneum while maintaining the efficacy of the open approach. One of the principal limitations of this approach is that it requires consistent experience with laparoscopy. Therefore, this technique remains an alternative in very selected patients and centers.

## References

- 1 Zhang JQ, Fielding JR, Zou KH: Etiology of spontaneous perirenal hemorrhage: a meta-analysis. *J Urol* 2002;167:1593–1596.
- 2 Albi G, del Campo L, Tagarro D: Wunderlich's syndrome: causes, diagnosis and radiological management. *Clin Radiol* 2002;57:840–845.
- 3 Brkovic D, Moehring K, Doersam J, Pomer S, Kaelble T, Riedasch G, et al: Aetiology, diagnosis and management of spontaneous perirenal haematomas. *Eur Urol* 1996;29:302–307.
- 4 Zagoria RJ, Dyer RB, Assimos DG, Scharling ES, Quinn SF: Spontaneous perinephric hemorrhage: imaging and management. *J Urol* 1991;145:468–471.
- 5 Chan YC, Morales JP, Reidy JF, Taylor PR: Management of spontaneous and iatrogenic retroperitoneal haemorrhage: conservative management, endovascular intervention or open surgery? *Int J Clin Pract* 2008;62:1604–1613.
- 6 Hernandez F, Ong AM, Rha KH, Pinto PA, Kavoussi LR: Laparoscopic renal surgery after spontaneous retroperitoneal hemorrhage. *J Urol* 2003;170:749–751.
- 7 Thanos A, Liakatas JL, Sotiriou V, Aristas O, Davillas N: Diagnostic and therapeutic dilemmas in nontraumatic spontaneous perirenal hemorrhage. *Eur Urol* 1991;19:217–220.
- 8 Hao LW, Lin CM, Tsai SH: Spontaneous hemorrhagic angiomyolipoma present with massive hematuria leading to urgent nephrectomy. *Am J Emerg Med* 2008;26:249.e3–e5.
- 9 Thiel R, Adams JB, Schulam PG, Moore RG, Kavoussi LR: Venous dissection injuries during laparoscopic urological surgery. *J Urol* 1996;155:1874–1876.
- 10 Gong EM, Zorn KC, Gofrit ON, et al: Early laparoscopic management of acute postoperative hemorrhage after initial laparoscopic surgery. *J Endourol* 2007;21:872–878.